

# The Use of Single Versus Multiple Doses Cefotaxime as a Prophylactic Antibiotic in Maxillofacial Fractures

**Atalla F Rejab**  
BDS, MSc, FIBMF (Lec.)

**Department Oral and Maxillofacial surgery**  
College of Dentistry, University of Mosul

**Mohammed K Hassouni**  
BDS, F.D.S.R.C.R.S (Lec)

**Department Oral and Maxillofacial surgery**  
College of Dentistry, University of Mosul

## الخلاصة

**الأهداف:** تهدف الدراسة الى تقييم فعالية استعمال جرعة واحدة من عقار سيفوتاكسيم بمقارنته مع نفس العقار عندما يستعمل لمدة خمسة أيام في منع ظهور عدوى الجروح الموضعية بعد عمليات علاج كسور الوجه والفكين. **المواد وطرائق العمل:** تكونت عينة الدراسة من (78) مريضاً مع اختلاف المستويات الاجتماعية والتعليمية للمرضى. جميع المرضى كانت لديهم كسور في منطقة الوجه والفكين والذين كانت ستجرى لهم عمليات تحت التخدير العام لعلاج كسور الوجه والفكين لديهم. تم تقسيم المرضى قبل العمليات إلى مجموعتين، المجموعة الأولى: تم إعطاء المرضى في هذه المجموعة جرعة واحدة من عقار سيفوتاكسيم (40 ملغم / كغم) من وزن الجسم عن طريق الوريد في بداية إعطاء التخدير العام، بعد ذلك لم يعطى المرضى أي جرعة أخرى. المجموعة الثانية: كل مريض في هذه المجموعة أعطي عقار سيفوتاكسيم (20 ملغم / كغم) من وزن الجسم عن طريق الوريد ولمدة خمسة أيام بواقع مرتين في اليوم. خلال مدة رقاد المرضى في المستشفى تم فحصهم مرتان يومياً لمراقبة أعراض عدوى الجروح الموضعية. بعد خروجهم من المستشفى تم استدعائهم أسبوعياً لفحص أعراض عدوى الجروح الموضعية في الأسبوع الأول والثاني والثالث والرابع. **النتائج:** أظهرت النتائج ان مريضاً واحداً فقط من المجموعة الأولى ظهرت لديه أعراض عدوى الجروح الموضعية من مجموع ثلاثة وأربعين مريضاً. أما في المجموعة الثانية فوجدت حالتان أظهرتا أعراض عدوى الجروح الموضعية من مجموع خمس وثلاثين حالة. **الاستنتاجات:** أثبتت هذه الدراسة فعالية عقار سيفوتاكسيم في منع ظهور عدوى الجروح الموضعية بعد عمليات علاج كسور الوجه والفكين. وعند مقارنة استعمال عقار سيفوتاكسيم جرعة واحدة أظهر نتائج مساوية أو أفضل من نتائج استعمال نفس الدواء لمدة خمسة أيام.

## ABSTRACT

**Aim:** The study aims to test the efficacy of using a single dose of cefotaxime antibiotic intravenously compared to the same drug when used for five days in the prevention of surgical site infection following maxillofacial fracture operations. **Materials and Methods:** The study group consisted of 78 patients of different social and educational levels who have sustained maxillofacial fractures. All patients were planned to undergo operative procedures under general anesthesia to treat their fractures. Patients were randomized preoperatively into two groups ( Group A and Group B). Each patient in group A received a single dose of cefotaxime sodium (claforan) 40mg/kg body weight given intravenously at the induction of general anesthesia. No further dose of any antibiotic was given subsequently. Each patient in group B received cefotaxime sodium intravenously 20mg/kg twice daily for five days, starting the first dose of cefotaxime sodium at the induction of general anesthesia. During hospitalization postoperatively, patients were examined for signs and symptoms of surgical site infection. After discharge, the patients were recalled to the clinic for post-operative examination at 1, 2, 3 and 4 weeks. **Results:** Only one patient out of 43 patients in the first group showed signs and symptoms of infection which was confirmed by culture and sensitivity test. Two cases of postoperative infection out of 35 patients developed infection in the second group. **Conclusions:** Using a single dose of cefotaxime was found to be comparable or even better than the use of the same drug for five days as a prophylactic antibiotic.

**Key Words:** Single dose, cefotaxime, prophylactic antibiotic, maxillofacial fracture, antibiotics and general anesthesia, cephalosporin.

Rejab AF, Hassouni MK. The Use of Single Versus Multiple Doses Cefotaxime as a Prophylactic Antibiotic in Maxillofacial Fractures. *Al-Rafidain Dent J.* 2012; 12(1): 96-101.

**Received:** 29/9/2010

**Sent to Referees:** 4/10/2010

**Accepted for Publication:** 14/11/2010

## INTRODUCTION

Antibiotic prophylaxis in surgery refers to the preoperative administration of antibiotics for the prevention or reduction of post-operative infection.<sup>(1-3)</sup> The signs and symptoms of an infection in the maxillofacial region are readily apparent within

days of an injury and manifested as pain, redness, and swelling of the face or neck, trismus, dysphagia, and drainage. Systemically, fever, lymphadenopathy, malaise, and an elevated white blood cell count are signs and symptoms of an infection.<sup>(4)</sup> Prophylactic administration of antibiotics

can decrease postoperative morbidity, shorten hospitalization, and reduce overall costs attributable to infections.<sup>(5-8)</sup> However, it is widely agreed by health authorities that it is necessary to reduce the total use of antibiotics to conserve antibiotics for use in life-threatening infections, to reduce the development of bacterial resistance, to minimize the chance of serious adverse reactions and to reduce cost.<sup>(9-11)</sup> A variety of prophylactic antibiotic regimens for maxillofacial trauma surgery has been investigated.<sup>(12)</sup> The chosen antibiotics for prophylaxis must be bactericidal, effective against bacteria that are most likely to cause infection, and the least toxic agent available.<sup>(13,14)</sup> In surgical operations, the intravenous route is most commonly used<sup>(10)</sup> and cephalosporins are commonly used in maxillofacial surgery because they achieve high concentrations in bone<sup>(15)</sup> and are broad-spectrum bactericidal antibiotics.<sup>(16,17)</sup>

It is not well demonstrated that the use of antibiotics for more than 24 hours after the surgery may further reduce the risk of infection. Therefore, it may be considered malpractice treating patients with antibiotics more than this period of time.<sup>(9,18)</sup> A single dose prior to commencement of the procedure is probably all that is required.<sup>(1,10)</sup> So, cefotaxime (claforan) which is a third generation cephalosporin will be tested in this study as a prophylactic antibiotic to prevent surgical site infection after maxillofacial trauma surgery.

## MATERIALS AND METHODS

### *Patients:*

The study group consisted of (78) patients of different social and educational levels who attended the Oral and Maxillofacial Surgery Unit in Aljumhuree Hospital at Mosul City. The patients have sustained fractures that involved the maxillofacial region. The period of the study extended from July 2008 to May 2009.

### *Materials and Instruments Used in Drug Administration*

1-Cefotaxime sodium vials 1 gram (LDP Laboratories TORLAN S.A., Spain).

2-Intravenous canulas (Medico, United Arab Emirates).

3-Disposable syringes 5 ml with needles gauge 23 (Becton Dickinson S.A., Spain).

### *History:*

Detailed history was taken from each patient. If the patient was a child, his or her guardian was asked the questions about the patient history to fill the case sheet.

### *Clinical Examination:*

Preoperative clinical examination of the patients was done that included inspection, percussion, and palpation and supplemented by radiographic views (including CT scans in some cases). Ordinary preoperative laboratory investigations were also done like complete blood picture, general urine examination, and fasting blood sugar. Chest x-rays and ECGs were also done if indicated.

### *Patient Selection:*

All patients with maxillofacial fractures were planned to undergo surgical procedures under endotracheal general anesthesia. Both elective and emergency operations were included. Patients with the following criteria were excluded:

Patients who show the signs and symptoms of local infections preoperatively.

Patients with medical conditions in which the host defence is compromised, e.g. diabetes mellitus.

Patients who are extremely old.

Patients with a history of allergy to penicillins or cephalosporins.

### *Patients Categorization:*

In this prospective study patients were randomized preoperatively into two groups (group A and group B) using a table of random number.

Group A: Each patient in this group received a single dose of cefotaxime sodium (claforan) 40mg/kg body weight given intravenously at the induction of general anesthesia. No further dose of any antibiotic was given subsequently.

Group B: Each patient in this group received cefotaxime sodium intravenously 20mg/kg twice daily for five days, starting the first dose of cefotaxime sodium at the induction of general anesthesia.

Treatment of maxillofacial fractures was done under general anesthesia and according to the type and site of fracture and degree of fracture displacement. The fractures were treated using either closed reduction and fixation or open reduction and interosseous or miniplate fixation or

Gillies approach and closed reduction for zygomatic fractures. During hospitalization postoperatively, each patient was examined twice daily for signs and symptoms of surgical site infection such as pain, redness, and swelling of the face or neck, trismus, dysphagia, and drainage. Systemically; fever, lymphadenopathy, malaise, and an elevated white blood cell.

After discharge, the patients were recalled for post-operative examination at the 1st, 2nd, 3rd, and 4th week. Data were

collected and analysed on pantium 4 computer.

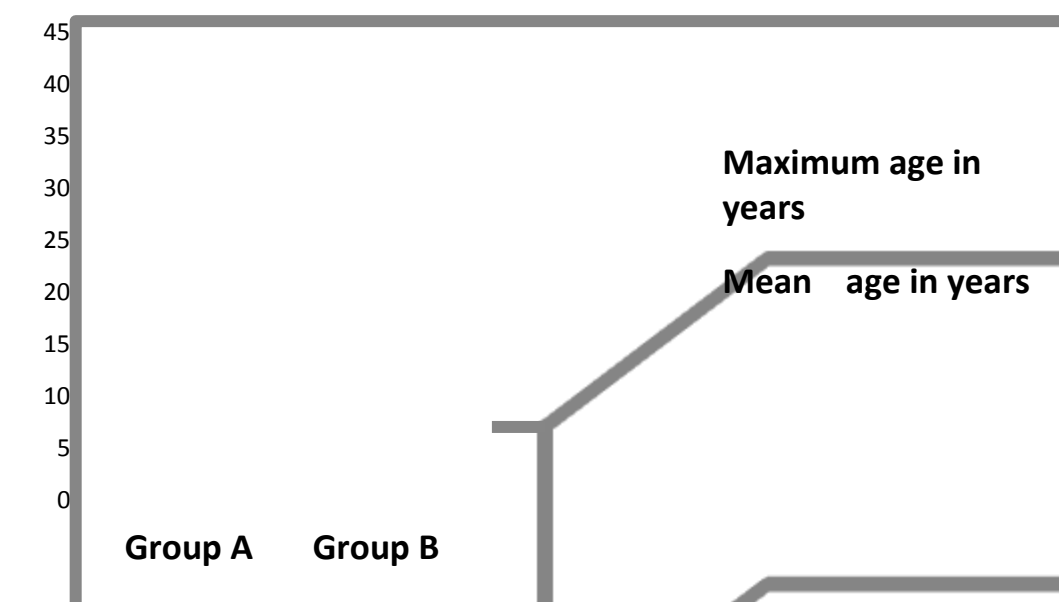
**RESULTS**

*Age and sex*

The age range of the sample was between (4-43) years with an average range of 24 years. The majority of the patients were found to be between 16 to 25 years old (43 out of 78, 55.12% ). In group A the patients age ranged from 4-32 years. In group B the patients age ranged from 12-43 years. (Table 1) and (Figure1).

Table (1): Age distribution of the sample

Group	Number of patients	Minimum age in years	Maximum age in years	Mean age
<b>Group A</b>	43	4	32	23
<b>Group B</b>	35	12	43	25



Figure(1) Mean , minimum and maximum age for the studied groups

The sex distribution was as follows: sixty five males (83.3%) and thirteen females (16.7%). There were 39 males ( 90.7 %)

and 4 females (9.3 %) in group A and 26 males (74.3%) and 9 females (25.7%) in group B and as shown in (Table 2).

Table (2): Sex distribution and percentage between groups.

Group	Number of males	Percent of males	Number of females	Percent of females	Total number	Total percent
<b>Group A</b>	39	90.7%	4	9.3%	43	100%
<b>Group B</b>	26	74.3%	9	25.7%	35	100%
<b>Total</b>	65	83.3%	13	16.7%	78	100%

*Infection Rate in Group A ( Single dose cefotaxime treated group ):*

Only one patient out of 43 patients in group A showed the signs and symptoms of infection which was confirmed by culture and sensitivity test. The patient was then successfully treated by ampiclox 500 mg 1x4 intravenously for seven days.

*Infection Rate in Group B (Five days cefotaxime treated group):*

Two cases of postoperative infection out of 35 patients developed infection in group B as shown in (Table 3). These two infections were treated successfully later using claforan 1 gram IV 1x2 for seven days.

Table (3): Number of the postoperative infection cases according to the groups.

Group	Number of cases	Infection cases
Group A	43	1
Group B	35	2

**DISCUSSION**

Antibiotics may cause a variety of unwanted effects. They promote antibiotic resistance and contribute to superinfection. Antibiotic use is also costly and associated with allergic reactions ranging from a minor skin rash to an anaphylactic reaction, toxic reactions including neural, renal, hepatic, hematopoietic, and gastrointestinal toxicity, and adverse effects. Because of these undesired effects, surgeons should use them cautiously.<sup>(13, 19, 20, 21)</sup>

Cephalosporins are commonly used in maxillofacial surgery for prophylaxis and treatment because they achieve high concentrations in bone.<sup>(15)</sup> Some believe that the higher activity and broader spectrum of cephalosporins would protect more patients more effectively from postoperative infections, especially when the surgical procedure is indicated for prophylaxis and the antibiotic chosen is well tolerated.<sup>(22)</sup> Cefotaxime (Claforan) which is a third generation cephalosporin was used in this study since it is widely used for major head and neck surgery including maxillofacial trauma surgery.<sup>(23)</sup> It is well tolerated and does not cause a significant incidence of coagulopathies, as observed with some cephalosporins, nor is it associated with the development of pseudocholelithiasis as seen with ceftriaxone.<sup>(24)</sup>

Antibiotic prophylaxis should be administered so that the antibiotic is present in the tissues of the wound in inhibitory concentrations beginning just before the initial incision and lasting at least through the duration of the operation<sup>(1)</sup>. Claforan was given intravenously before the begin-

ning of the surgical procedure.

For procedures under local anesthesia, antibiotics can be given orally providing that this route is not contraindicated but for procedures under general anesthesia antibiotics should be given intravenously at the induction of general anesthesia.<sup>(25)</sup> In the present study the antibiotic was given intravenously at the induction of general anesthesia. The first dose of the prophylactic antibiotic should be given at least double the usual therapeutic dose.<sup>(25)</sup> The usual therapeutic dose of claforan is 20 mg/kg body weight.<sup>(26)</sup> In group A the dose of claforan is 40mg/kg which is double the therapeutic dose. This was to achieve high inhibitory concentration of the antibiotic at the time of bacterial growth. When surgery was prolonged, subsequent intraoperative doses were required and given at the therapeutic dose.<sup>(25)</sup> This usually follows the plasma half life of the antibiotic. For example, four hours for a cephalosporin which is usually given eight hourly.<sup>(14,27, 28)</sup> However, no surgical procedure in the present study lasted longer than 4 hours which is the plasma half life of claforan.<sup>(28)</sup> The infection rates in the short-term and long-term cefotaxime (claforan) in the present study were 2.3 % and 5.7 %, respectively. One infection was observed in the regimen of prophylactic antibiotic given to group A (single dose claforan treated group) and two were observed in the regimen of prophylactic antibiotic given to group B. The case of infection in group A was found in a male child, 12 years old who sustained a fracture involving the body of the mandible

through the right molar tooth and there was a wound in the submandibular region. The fracture was treated by closed reduction and intermaxillary fixation. This case was a type of compound fracture which has a higher infection rate than simple fracture.<sup>(29-31)</sup> Two patients in group B developed infection postoperatively. The first patient was a male, 35 years old, the cause of fracture was a blast injury to the orbital region and zygoma. He was treated by open reduction through the wound and interosseous wiring. He developed infection at the seventh postoperative day. This was also a case of compound fracture which also has a higher infection rate than simple fractures.<sup>(29-31)</sup> The other patient was a male, twenty five years of age, with comminuted fracture of the mandible and loss of soft and hard tissues which was also a case of compound fracture. No infection was found in simple fractures (those not involving the teeth or are not opened through the skin). This is in agreement with other studies which confirm the low infection rate in simple facial fractures with or without the use of prophylactic antibiotics.<sup>(30,31)</sup>

### CONCLUSION

The use of a single dose cefotaxime as a prophylactic antibiotic given at the induction of general anesthesia is a safe, cost-effective and indicated method of reducing the incidence of postoperative infection in maxillofacial trauma surgery. A single dose of a prophylactic antibiotic given immediately before the surgical procedure may be sufficient to prevent postoperative infection.

### REFERENCES

1. Sader HS, Jones RN. Cefotaxime is extensively used for prophylaxis. *Am Med J Surg.* 1992; 164(4A Suppl): 28s-38s.
2. Munckoff W. Antibiotics for surgical prophylaxis. *Aust Prescriber.* 2005; 28: 38-40.
3. Jose VB, Antonio B, Rafael L, Jaime L, Araceli M, Blas N, Paloma P, Jose P, Jose IS. Consensus document on the use of antibiotic prophylaxis in dental surgery and procedures. *Oral Surgery Med Oral Patol*

- Oral Cir Bucal.* 2006; 11: E188-205.
4. Haug R, Assael L. Infection in the maxillofacial trauma patient. In: Topazian R, Goldberg M, Hupp J, eds: *Oral and Maxillofacial Infections.* Philadelphia, PA: WB Saunders. 2002; 359-380.
5. Anders A, Nordhausen B, Zeuschner Z, Fabrizio K. Prevention of infections in surgery of the colon. *Zentralbl Chir.* 1984; 109(17), 1097 - 1106.
6. Mansani FE, Caltabiano M, Condemi V, Scarpignato C. Short- or long-term antibiotic prophylaxis in obstetric and gynecologic laparotomy? *Acta Biomed Ateneo Parmense.* 1984; 55: 147-151.
7. Heydemann JS, Nelson CL. Short-term preventive antibiotics. *Clin Orthop.* 1986; 205:184-187.
8. Mandell-Brown M, Johnson JT, Wagner RL. Cost-effectiveness of prophylactic antibiotics in head and neck surgery. *Otolaryngol Head Neck Surg.* 1984; 92(5): 520-523.
9. Scottish Intercollegiate Guidelines Network. Antibiotic Prophylaxis in Surgery. SIGN Publication Number 104, July, 2008.
10. Lawler B, Sambrook PJ, Goss AN. Antibiotic prophylaxis for dento-alveolar surgery: Is it indicated? *Aust Dent J.* 2005; 50 Suppl 2:S54-S59.
11. Ruggles JE, Hann JR. Antibiotic prophylaxis in intraoral orthognathic surgery. *J Oral Maxillofac Surg.* 1984; 42(12): 797-801.
12. Jose IS, Alvaro DA. Antibiotic prophylaxis in Oral and Maxillofacial Surgery. *Med Oral Patol Oral Cir Bucal.* 2006;11:E292-296.
13. Baqain ZH, Hyde N, Patrikidou A, Harris M. Antibiotic prophylaxis for orthognathic surgery: a prospective, randomised clinical trial. *Br J Oral Maxillofac Surg.* 2004; 42: 506-10.
14. Ruggles JE, Hann JR. Antibiotic prophylaxis in intraoral orthognathic surgery. *J Oral Maxillofacial Surg.* 1984; 42: 797-801.
15. Effect of prophylactic intravenous ceftriaxone in maxillofacial surgery. *Chemotherapy,* 1987; 33(4):291-6. Links.
16. Bauer AW, Kirby WM, Sherris JC., Turck M. Antibiotic susceptibility testing by a standardized single disk method. *Am J Clin Pathol.* 1966;45:493-496.

17. Cockcroft DW, Gault MH. Predication of Creatinine Clearance from Serum Creatinine. *Nephron*. 1976. 16:31-41.
18. Classen DC, Evans RS, Pestotnic SL, Horn SD. The timing of prophylactic administration of antibiotics and the risk of surgical wound infection. *New Eng J Med* .1992; 326 (5):281-286.
19. Peterson LJ , Booth DF. Efficacy of antibiotic prophylaxis in intraoral orthognathic surgery. *J Oral Surg*. 1976; 34: 1088-1091.
20. Yannick JE, Rolf MA, Maurice YM, JO A, Herman W V, Johan VS, calix AS, Philippe RB, Luc FN. A prospective study on infectious complications in orthognathic surgery. *J Craniomaxillofac Surg*. 2005; 33: 24-29.
21. Zijderveld SA, Smeele LE, Kostense PJ, Tuinzing DB. Preoperative antibiotic prophylaxis in orthognathic surgery: a randomized, double-blind, and placebo-controlled clinical study. *J Oral Maxillofac Surg* .1999; 57: 1403-1406.
22. Blomer R, Bruch K. Review of the experience with cefotaxime in surgical prophylaxis. *Int J Clin Pharmacol Res*.1985; 5(3): 185–191.
23. Jones RN. Review of cefotaxime sodium for surgical prophylaxis. A model for the evolution toward single-dose or short-course cost-effective regimens. *Diagn Microbiol Infect Dis*. 1990;13(4): 317–327.
24. Plosker GL, Foster RH, Benfield P. Cefotaxime A review of its use in the treatment of infections. *Pharmacoeconomics*. 1998;13:91-106.
25. Clinical Practice Guidelines. Antibiotic prophylaxis against wound infection in oral surgical procedures. Ministry of Health of Malaysia publication. January, 2003.
26. British National Formulary. London, BJM Publishing Group, September 2005.
27. Peterson L J. Antibiotic prophylaxis against wound infections in oral and maxillofacial surgery. *J Oral Maxillofac Surg*. 1990; 48: 617-620.
28. Paul ST, Sanders N, Patel N, Talbot TR, Deshpande JK, Higgins M. Improving Timely Surgical Antibiotic Prophylaxis Redosing Administration Using Computerized Record Prompts. *Surgical Infections*. 2005; 6:215-221.
29. Maloney P L, Lincoln R E, Coyne C P. A protocol for the management of compound mandibular fractures based on the time from injury to treatment. *J Oral Maxillofac Surg*. 2001;59:879-884.
30. Abubaker AO, Rollert MK. Postoperative antibiotic prophylaxis in mandibular fractures: A preliminary randomized, double-blind, and placebo-controlled clinical study. *J Oral Maxillofac Surg*. 2001; 59: 1415-1419.
31. Heit JM, Stevens MR, Jeffords K. Comparison of ceftriaxone with penicillin for antibiotic prophylaxis for compound mandible fractures. *Oral Surg Oral Med Oral Pathol Oral Radiol Endod*. 1997; 83: 423-426.